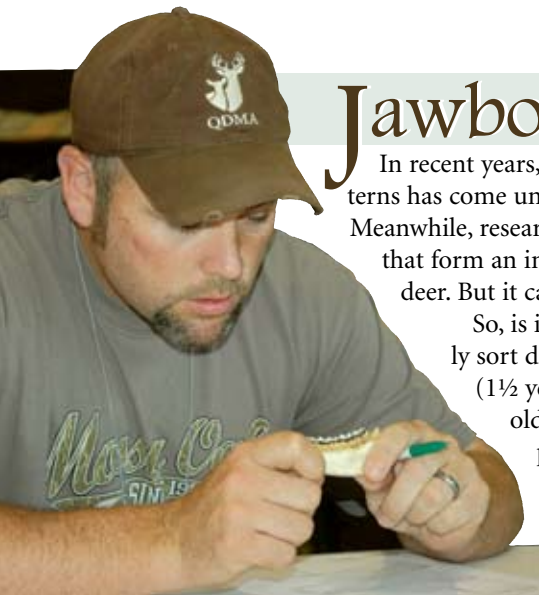

# Jawbone Talk



QDMA.COM

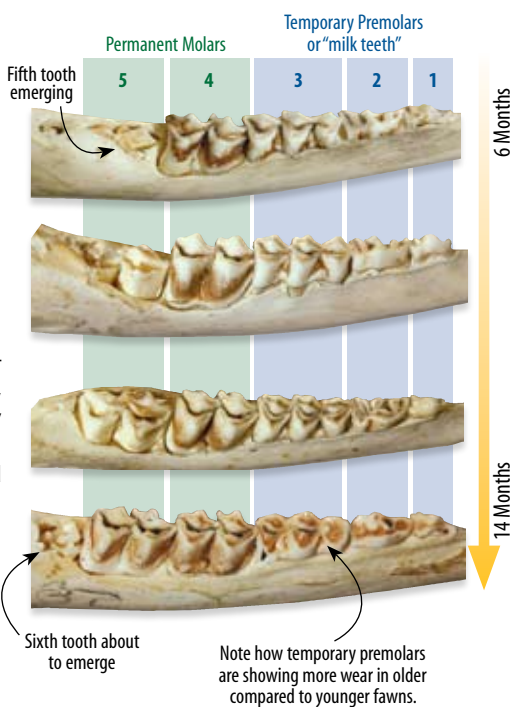
In recent years, the technique of aging deer based on tooth replacement and wear patterns has come under scrutiny, with experts questioning whether the method is reliable. Meanwhile, research has shown the *cementum annuli* method, where the calcium layers that form an incisor tooth are analyzed in a lab, to be more reliable for aging older deer. But it can't be done in the field, and it comes with a price tag.

So, is it still a good idea to collect jawbones from every deer you harvest? Yes! You can confidently sort deer into three groups based on tooth replacement patterns alone: 1) fawns, 2) yearlings (1½ years old), and 3) adults 2½ and older. After that, you can separate adults into young and old adults based on tooth wear patterns. The resulting information will be useful in all QDM programs, and it is particularly useful for does. That's good, because few of us would pay to have a doe's incisor tooth analyzed by a professional lab. But the greater precision in estimating the age of adult deer is very useful for mature bucks.

Here's an overview of the tooth eruption and wear patterns that can be used to identify **fawns**, **yearlings**, **middle-aged adults**, and **mature adults**.

## Fawns

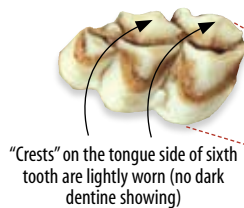
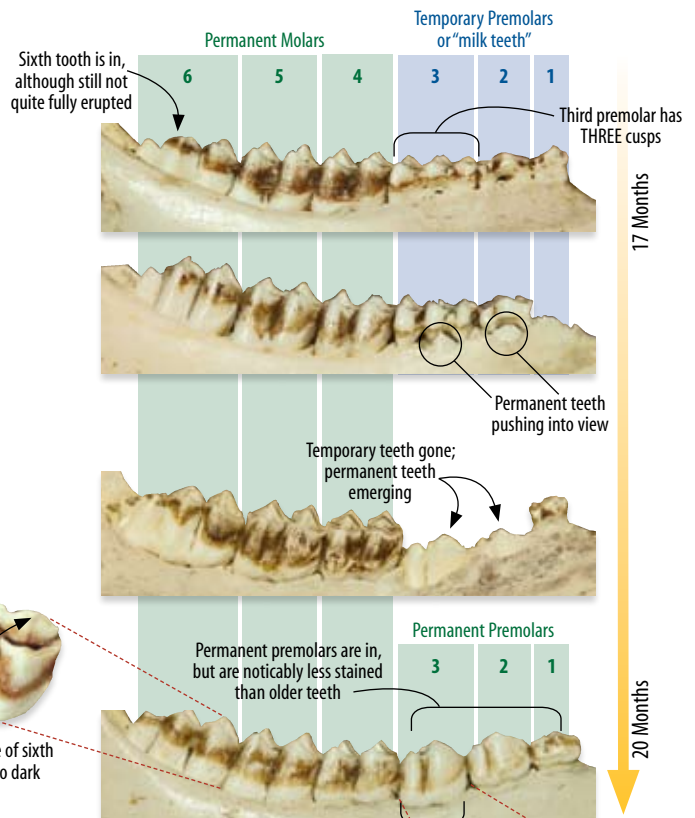
At birth, fawns have three temporary premolars (blue bands) on each lower jaw, and permanent molars begin to appear over the months that follow (green bands). Fawns (6 to 11 months of age) harvested during hunting season will have four to five completely erupted teeth, and a sixth tooth may be visible in early-born fawns harvested late in the fall.



**KEY: Fawns have less than six teeth in the lower jaw.**

## Yearlings

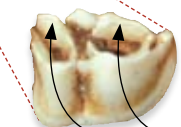
By 17 to 19 months of age, deer have a full set of six teeth on each lower jaw, including the temporary premolars (now well worn). The third temporary premolar has three "cusps." Thus, a jawbone with six erupted teeth and a three-cusped premolar is a yearling. This premolar is eventually replaced by a two-cusped permanent tooth. Early born or late-harvested yearlings may have acquired this tooth, but it will look new, showing little stain or wear.



"Crests" on the tongue side of sixth tooth are lightly worn (no dark dentine showing)

**KEY: Yearlings have six fully erupted teeth and a three-cusped premolar in the third position, OR a new-looking, two-cusped premolar in the third position.**

*An early-born and/or late-harvested yearling can be confused with a 2½-year-old due to having six permanent teeth. However, the premolars of the yearling will be less stained, and the cusps will be sharp and pointed with very little wear.*



"Crests" on the tongue side of third tooth are lightly worn (no dark dentine showing)

Need equipment for collecting jawbones, or a detailed poster to assist in analyzing tooth patterns? Visit the online store at [www.QDMA.com](http://www.QDMA.com)



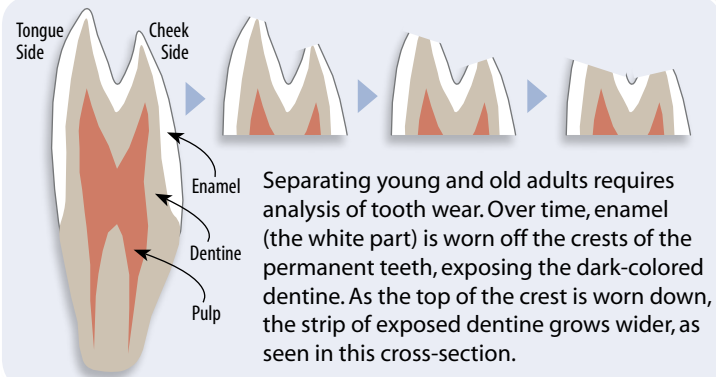
# Adults

Once a deer is determined to be at least 2½, tooth wear patterns are used to assign deer to older age classes. This portion of the aging technique is more subjective given the variation in observer experience, habitat quality, management approach, and tooth-wear patterns among individual deer. Because of this, attempting to assign a specific age beyond 2½ is recommended only for those with considerable experience aging deer in the location in question.

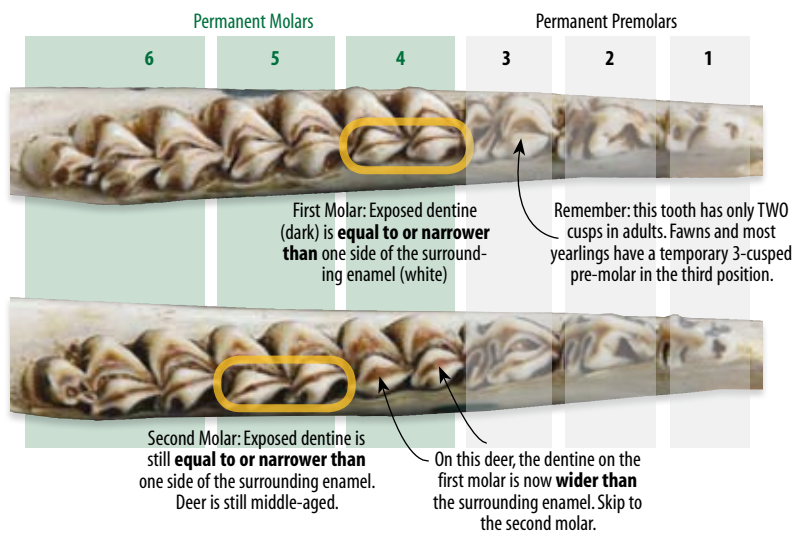


QDMA.COM

For all others, we recommend sorting adult deer into two groups: middle-age adults (2½ and 3½) and mature adults (4½-plus). When combined with fawns and yearlings, these four age groups will provide sufficient information from which to base most management decisions. If more specific age information is needed to establish or confirm buck-harvest guidelines, you can submit incisor teeth to a commercial lab for cementum analysis (counting growth rings) or seek assistance from a trained wildlife biologist.

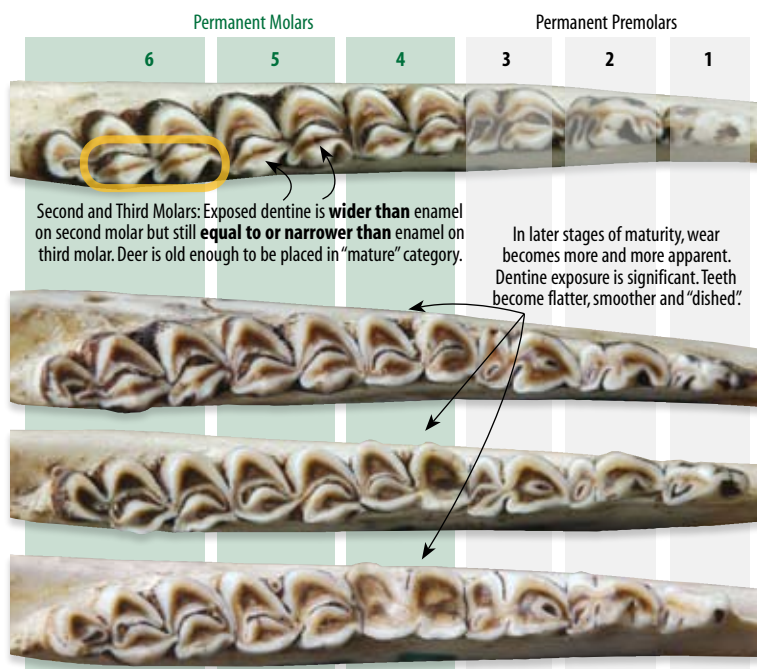


Separating young and old adults requires analysis of tooth wear. Over time, enamel (the white part) is worn off the crests of the permanent teeth, exposing the dark-colored dentine. As the top of the crest is worn down, the strip of exposed dentine grows wider, as seen in this cross-section.



## Middle-Age Adults (2½ and 3½)

Recall that any lower jawbone with six fully erupted teeth and a 2-cusped tooth in the third position is at least 2½ (unless that third tooth is noticeably “new,” as with some late-harvested yearlings). Once you’ve established the jawbone is from an adult, move on to tooth 4. Focus on the crest on the tongue-side of the tooth. The thin, dark band is exposed dentine. Over time, as the crests wear down, the dark band will equal and eventually exceed the width of the surrounding enamel (see the diagram at the top of the page). But at 2½, on tooth 4 this band will still be narrower than the enamel. If it’s equal to or wider than the enamel, it’s probably older than 2½. Move on to tooth 5 and repeat the question: wider or narrower? If the answer is “wider” on both tooth 4 and 5, this deer is moved up to the “mature” category.



## Mature Adults (4½~plus)

As you move along the jaw, studying the dentine width on the tongue-side of each molar, continue to ask if the dentine is equal to or wider than the surrounding enamel. If the answer is “yes” for tooth 4 and 5, the deer is likely older than 3½ – place it in the “mature adult” category. After this point, the wear on tooth 6 (the last tooth) will also eventually cause the dentine to exceed the width of the enamel. From here on, accuracy in attempting to label specific age classes is very low – and not necessary for herd-monitoring needs. A deer with six flattened, dished teeth is *old* – period.

**SELF-CHECK:** As with any data collection method, compare your jawbone age estimates against other locally collected data in your possession, such as body weights and, for bucks, antler measurements. If the jawbone is from a buck that was photographed by a trail-camera, how does your jawbone age compare with your photo age estimate? Finally, regularly check your jawbone estimates with a cementum age analysis from a lab – especially for mature bucks.